

## 63

## Major Pancreatic Resection for Chronic Pancreatitis: Indication, Goals, and Limitations

Faik G. Uzunoglu and Jakob R. Izbicki

Department of General Visceral and Thoracic Surgery, University of Hamburg Medical Institutions, Hamburg, Germany

### Definition of Chronic Pancreatitis

A multidisciplinary expert consensus proposed a new mechanistic definition of chronic pancreatitis (CP) in 2016 [1]. CP is defined as “a pathologic-fibro-inflammatory syndrome of the pancreas in individuals with genetic, environmental and/or other risk factors who develop persistent pathological responses to parenchymal injury or stress.” Major international societies have adopted the mechanistic approach. It is based on a conceptual model with five stages ranging from A (at risk) to E (end-stage CP) (Fig. 63.1).

### Timing and Goals of Major Pancreatic Resections

Based on the mechanistic approach, surgical therapeutic interventions need to take place in stage C (early CP) or stage D (established CP) rather than in stage E (end-stage CP) with irreversible features and complications of CP.

Therefore, a potential surgical intervention needs to occur months after the initial acute pancreatitis event (early CP, stage C). To facilitate preventive and therapeutic interventions in time, it requires a multidisciplinary team (gastroenterologists, advanced endoscopists, radiologists, pancreatic surgeons, pain, and nutritional specialists), which initiates diagnostics and therapeutic interventions at the sentinel event, since up to 35% of patients with an initial episode of acute pancreatitis will develop CP within 3–8 years [2,3].

The basis of any intervention in time is an accurate diagnosis of early CP. The mechanistic definition includes a second part: “Common features of established and advanced CP include pancreatic atrophy, fibrosis, pain syndromes, duct distortion and strictures, calcifications,

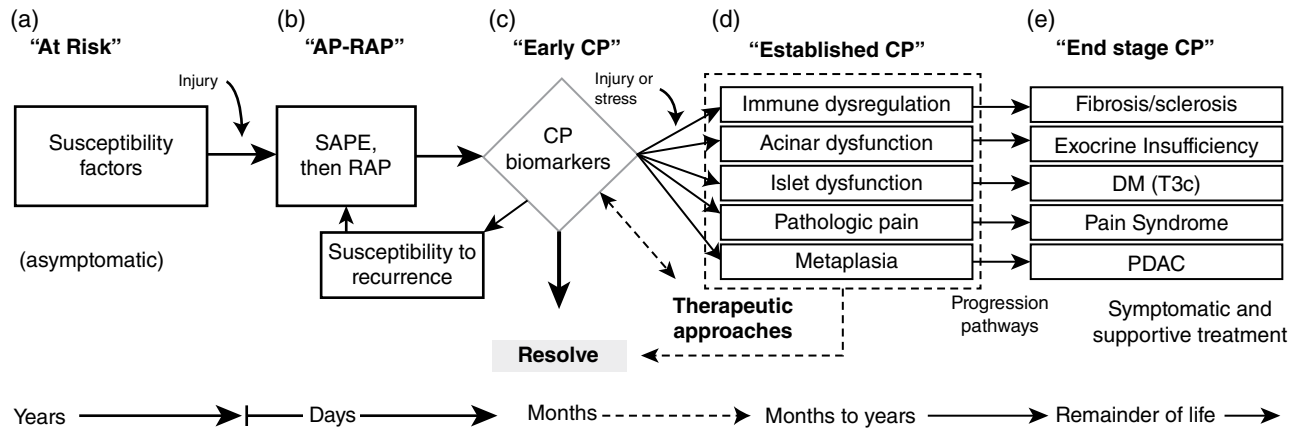
pancreatic exocrine dysfunction, and dysplasia.” Therefore, the mechanistic definition does not require prominent imaging features to diagnose early CP. Unfortunately, a consensus for a definition of early CP or diagnostic criteria could not be established within the international working group in 2017 [4].

Until consensus is reached, potential surgical interventions remain based on imaging combined with patients’ pain burden.

While computed tomography is the most appropriate baseline imaging modality for CP, it cannot exclude a CP or be used exclusively to diagnose early CP (stage C). Magnetic resonance cholangiopancreatography (MRCP) and secretin-stimulated MRCP are more accurate for detecting subtle changes in the early stages. The role of endoscopic ultrasound is limited to inconclusive MRCP results or (planned) therapeutic interventions [5]. ERCP should not be used for diagnostic purposes [6].

The conceptual model predetermines successful interventions as early as possible to prevent end-stage CP with fibrosis/sclerosis, exocrine and endocrine insufficiency, and chronic pain syndrome. The goal of surgical intervention in time can only be reached if the old paradigm “surgery is the last option” is abandoned. Surgery in an early stage of CP has the potential to achieve the main goals, namely, to mitigate disease progression, pain control without chronic opioid dependency, and restore quality of life [7,8], preserve exocrine function [9], prevent rather than manage local complications (bile duct or bowel obstruction, portal vein compression, splenic vein thrombosis, fistula, or pseudocyst and pseudoaneurysms/erosion of large vessels).

While the change of lifestyle and conservative treatment will often remain the first step, the period of medical pain management should be limited by the multidisciplinary team from the beginning due to the risk of opioid



**Figure 63.1** The basis of the mechanistic approach is a conceptual model of CP. AP-RAP: acute pancreatitis and recurrent acute pancreatitis; CP: chronic pancreatitis; DM (T3c): diabetes mellitus type IIIc or pancreatogenic diabetes mellitus; PDAC: pancreatic ductal adenocarcinoma; SAPE: sentinel acute pancreatitis event. Source: Whitcomb et al. 2016 [1]. With permission of Elsevier.

dependency and the development of neuropathic pain [10]. Failure of conservative pain management should lead to discussing endoscopic and surgical options as equivalent options for first-line interventional treatment within the multidisciplinary team and the patient. The treatment advice should consider the following data: early surgery leads to more pain relief and less postoperative opioid use [9,11–14], multiple endoscopic interventions are associated with reduced success in terms of long-term pain relief after surgery [8], and 40–75% of CP patients will require surgery in the course of the disease [15]. Most recently, the randomized ESCAPE trial results support these findings [16]. The early surgery approach was superior, with lower pain scores over 18 months than the endoscopy first approach. Complete pain relief was achieved in almost 60% of the early surgery group vs. 40% in the endoscopy first group. One-third of patients in the endoscopy group were referred to undergo surgery because of failed endoscopic treatment.

### Limitations of Major Pancreatic Resections

Although surgical intervention is a significant key to success in patients suffering from CP, some circumstances limit surgical options. In advanced stages of CP cachexia, severe malnutrition, and sarcopenia are often evident and associated with higher perioperative morbidity and mortality [17]. Accordant nutritional therapeutic options must be considered before surgery to obtain optimal surgical results. A complete portal thrombosis with portal hypertension is a relative contraindication for surgery. The risk of bleeding and perioperative complications is significantly increased in this subgroup of patients.

Preoperative recanalization of the mesentericoportal axis with subsequent surgery should be limited to high-volume centers with accordant expertise [18–20].

### Surgical Strategies Based on Morphological Characteristics

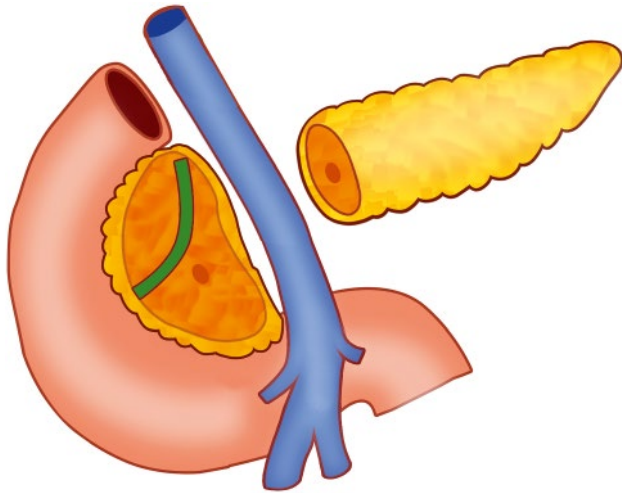
Surgical interventions need to be based on the following goals:

- Effective in terms of long-term pain management and local complications (restore quality of life);
- Preservation of maximum endocrine and exocrine function;
- Safety (low morbidity and mortality);
- Long-term sufficient drainage of the pancreatic duct.

Based on these goals, the primary surgical strategies and indications will be summarized and expanded upon in subsequent chapters. The recommendations are based on the international consensus guidelines published in 2019 [21]. Differing treatment strategies at the authors' institution are emphasized if indicated.

#### Chronic Pancreatitis with Enlarged Pancreatic Head without Strictures or Stones in Pancreatic Corpus and Tail

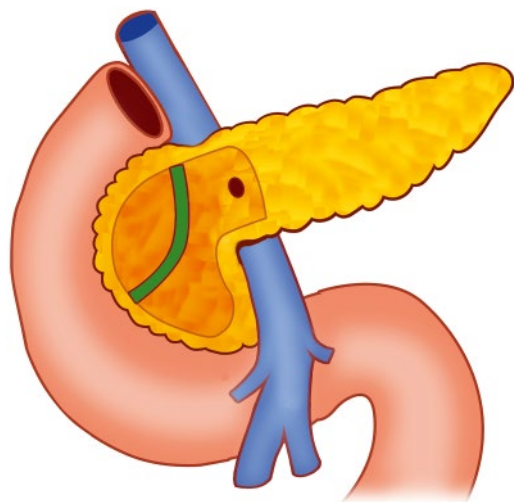
In patients with a morphology characterized by a solely enlarged pancreatic head (inflammatory mass) without pathologies in the pancreatic corpus or tail, a duodenum-preserving pancreatic head resection (DPPHR) may be the treatment of choice. All DPPHR procedures have the advantage of maintaining the physiological gastroduodenal passage and common bile duct continuity.



**Figure 63.2** Beger procedure: subtotal resection of the pancreatic head with transection of the pancreas above the portal vein. Source: Faik G. Uzunoglu.

DPPHR variations in these patients consist of the Beger- or Berne procedure. The Beger procedure is characterized by a subtotal resection of the pancreatic head with transection of the pancreas above the portal vein (Fig. 63.2). The Berne procedure avoids a complete transection of the pancreas above the portal vein (Fig. 63.3). The inflammatory periportal fibrosis with or without portal vein thrombosis carries a high risk of bleeding complications that might be difficult to control.

An alternative to DPPHR variations is the (pylorus-preserving) pancreaticoduodenectomy. This procedure is often not the treatment of choice because of surrounding vessels' involvement by the pancreatic head's inflammatory mass. In terms of long-term pain relief,



**Figure 63.3** Berne procedure: avoidance of complete transection of the pancreas above the portal vein. Source: Faik G. Uzunoglu.

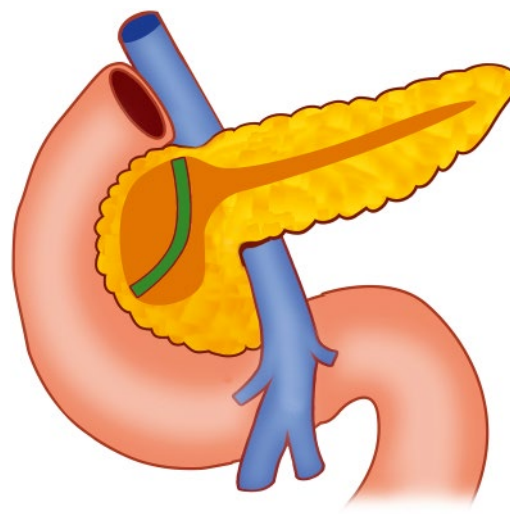
no differences are evident, as well as regarding morbidity, pancreatic fistula rate, or operative time. The DPPHR group was superior in quality of life, postoperative weight gain, and more exocrine function impairment within a systematic review and meta-analysis [22].

At the authors' institution, the (pylorus-preserving) pancreaticoduodenectomy is only the treatment of choice in uncertain cases with high suspicion of malignancy and if malignancy cannot be ruled out securely by frozen section analysis or in case of bowel obstructions that cannot be resolved sufficiently by DPPHR.

### Chronic Pancreatitis with Dilated Main Duct with or without Enlarged Pancreatic Head

In patients with a morphology characterized by duct dilatation  $\geq 5$  mm with or without an enlarged pancreatic head, a modified DPPHR such as the Frey or Hamburg procedure may be the treatment of choice.

Like the Berne procedure, the Frey procedure does not include the division over the superior mesenteric portal vein. Still, it combines the DPPHR with a longitudinal opening of the pancreatic duct up to 1–2 cm from the splenic hilum (Fig. 63.4). While the Frey procedure is the treatment of choice for patients with main duct dilatation with an enlarged pancreatic head, sufficient data is lacking on whether the Frey procedure or solely the longitudinal opening of the pancreatic duct should be preferred in patients with standard size pancreatic head. If the surgeon's choice of treatment favors the longitudinal opening solely, it should be done in an extended manner within 1 cm of the duodenum to decompress the



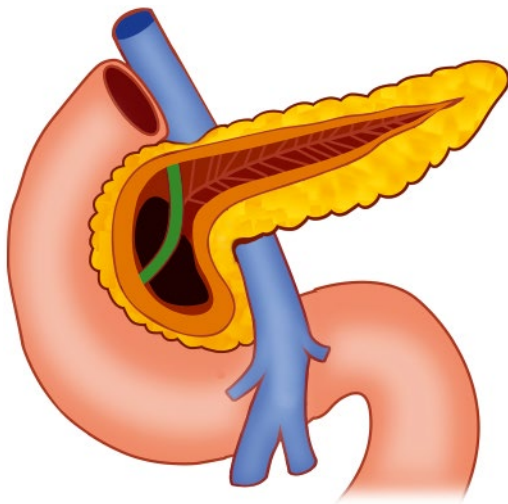
**Figure 63.4** Frey procedure: limited pancreatic head resection, avoidance of complete transection of the pancreas above the portal vein, longitudinal opening of the pancreatic duct. Source: Faik G. Uzunoglu.

complete pancreatic duct, including Wirsung and Santorini's ducts [23,24].

At the authors' institution the standard of care in patients with or without enlargement of the pancreatic head is the "Hamburg procedure" (Fig. 63.5). Like the Frey and Berne procedures, the division of the pancreas above the mesentericoportal axis is avoided. Still, comparable to the Berne procedure, the extent of the coring of the pancreatic head is customized to the individual morphology of the pancreas and extended, including the uncinata process if necessary. The extended coring of the pancreatic head, including the uncinata process compared to Frey, secures the bile duct decompression to the full extent and prevents a potential recurrence of common bile duct compressions. At the same time, decompression of the complete pancreatic duct system, including Wirsung and Santorini's ducts, is assured.

If, during the decompression of the intrapancreatic common bile duct, an injury to the intrapancreatic bile duct occurs, reinsertion of the distal common bile duct into the pancreatic resection cavity is frequently performed. Considering the high incidence of anastomotic strictures after reinsertion [25], this procedure has been abandoned at the authors' institution, and the DPPHR procedure is combined with a bilioenteric anastomosis.

Regarding the longitudinal opening of the pancreatic duct in the body and tail of the pancreas, the Hamburg procedure is characterized by a V-shaped opening of the main pancreatic duct instead of the solely longitudinal opening during the Frey procedure. The rationale here is



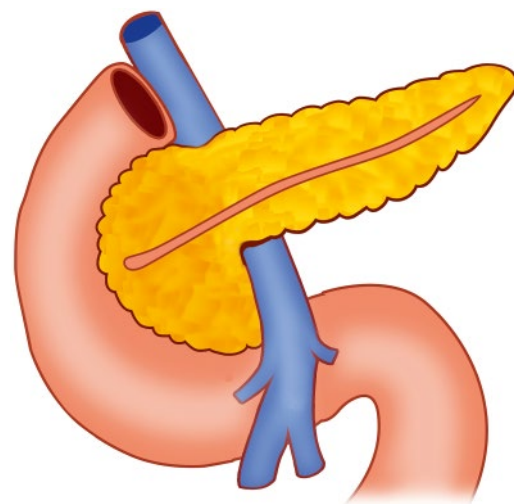
**Figure 63.5** Hamburg procedure: avoidance of complete transection of the pancreas above the portal vein, extended coring of the pancreatic head, including the uncinata process. V-shaped opening of the main pancreatic duct for drainage of side branches of second- and third order for securing long-term drainage of the pancreatic body and tail. *Source:* Faik G. Uzunoglu.

the drainage of pancreatic duct side branches of second- and third order for securing long-term drainage of the pancreatic body and tail, especially in sclerosing (small duct) CP or extended calcifications of the pancreatic parenchyma in the pancreatic body and tail [26].

### Chronic Pancreatitis with Isolated Left-Sided Strictures or Stones without Enlarged Pancreatic Head

In patients with left-sided symptomatic stones that are not reachable for endoscopic interventions, including extracorporeal lithotripsy, as well as in patients with left-sided strictures or complete duct disruption (e.g., after acute necrotizing pancreatitis) with patent pancreatic head and body, the longitudinal opening of the left-sided pancreatic duct (Partington and Rochelle) may be the treatment of choice (Fig. 63.6). Distal pancreatectomies should be avoided to prevent impaired exocrine function whenever possible.

At the authors' institution, the longitudinal opening is performed V-shaped. In selected cases and depending on the morphology of the pancreas, the senior author performs a stapled complete transection of the pancreas (if necessary, including a segmental resection) before the dilated duct area followed by a V-shaped resection of the remnant left-sided pancreas with accordant drainage by a Roux limb. From the authors' point of view, the complete transection often allows a safer anastomosis to the left-sided pancreatic remnant. Indications for concurrent splenectomy in this setting include a perisplenic pseudocyst, splenic vein thrombosis, or fibrotic encasement of the splenic vessels.



**Figure 63.6** Extended Partington and Rochelle: longitudinal opening of the left-sided pancreatic duct within 1 cm of the duodenum to decompress the complete pancreatic duct, including Wirsung and Santorini's duct. *Source:* Faik G. Uzunoglu.

## References

- Whitcomb DC, Frulloni L, Garg P et al. Chronic pancreatitis: an international draft consensus proposal for a new mechanistic definition. *Pancreatology* 2016;16(2):218–224.
- Ali UA, Issa Y, Hagensars JC et al. Risk of recurrent pancreatitis and progression to chronic pancreatitis after a first episode of acute pancreatitis. *Clin Gastroenterol Hepatol* 2016;14(5):738–746.
- Sankaran SJ, Xiao AY, Wu LM et al. Frequency of progression from acute to chronic pancreatitis and risk factors: a meta-analysis. *Gastroenterology* 2015;149(6):1490–1500.e1.
- Whitcomb DC, Shimosegawa T, Chari ST et al. International consensus statements on early chronic pancreatitis. Recommendations from the working group for the international consensus guidelines for chronic pancreatitis in collaboration with the International Association of Pancreatology, American Pancreatic Association, Japan Pancreas Society, PancreasFest Working Group, and European Pancreatic Club. *Pancreatology* 2018;18(5):516–527.
- Frøkjær JB, Akisik F, Farooq A et al. Guidelines for the diagnostic cross-sectional imaging and severity scoring of chronic pancreatitis. *Pancreatology* 2018;18(7):764–773.
- Hoffmeister A, Mayerle J, Beglinger C et al. English language version of the S3-consensus guidelines on chronic pancreatitis: definition, aetiology, diagnostic examinations, medical, endoscopic and surgical management of chronic pancreatitis. *Zeitschrift Für Gastroenterologie* 2015;53(12):1447–1495.
- Machicado JD, Amann ST, Anderson MA et al. Quality of life in chronic pancreatitis is determined by constant pain, disability/unemployment, current smoking, and associated co-morbidities. *Am J Gastroenterol* 2017;112(4):633–642.
- Ali UA, Nieuwenhuijs VB, Eijck CH van et al. Clinical outcome in relation to timing of surgery in chronic pancreatitis: a nomogram to predict pain relief. *Arch Surg* 2012;147(10):925–932.
- Riediger H, Adam U, Fischer E et al. Long-term outcome after resection for chronic pancreatitis in 224 patients. *J Gastrointest Surg* 2007;11(8):949–960.
- Bouwense SAW, Olesen SS, Drewes AM et al. Is altered central pain processing related to disease stage in chronic pancreatitis patients with pain? An exploratory study. *PLoS ONE* 2013;8(2):e55460.
- Ali UA, Pahlplatz JM, Nealon WH et al. Endoscopic or surgical intervention for painful obstructive chronic pancreatitis. *Cochrane Database Syst Rev* 2015;3(3):CD007884.
- Ke N, Jia D, Huang W et al. Earlier surgery improves outcomes from painful chronic pancreatitis. *Medicine* 2018;97(19):e0651.
- Nealon WH, Thompson JC. Progressive loss of pancreatic function in chronic pancreatitis is delayed by main pancreatic duct decompression a longitudinal prospective analysis of the modified Puestow procedure. *Ann Surg* 1993;217(5):458–468.
- Yang CJ, Bliss LA, Schapira EF et al. Systematic review of early surgery for chronic pancreatitis: impact on pain, pancreatic function, and re-intervention. *J Gastrointest Surg* 2014;18(10):1863–1869.
- Warshaw AL, Banks PA, Castillo CF. AGA technical review: treatment of pain in chronic pancreatitis. *Gastroenterology* 1998;115(3):765–776.
- Issa Y, Kempeneers MA, Bruno MJ et al. Effect of early surgery vs endoscopy-first approach on pain in patients with chronic pancreatitis. *JAMA* 2020;323(3):237–247.
- Schnelldorfer T, Adams DB. The effect of malnutrition on morbidity after surgery for chronic pancreatitis. *Am Surg* 2005;71(6):466–473.
- Fragua RAL, Vázquez AM, Marcano AJL et al. Pancreatic surgery in chronic pancreatitis complicated by extrahepatic portal hypertension or cavernous transformation of the portal vein: a systematic review. *Scand J Surg* 2019;109(3):177–186.
- Bockhorn M, Gebauer F, Bogoevski D et al. Chronic pancreatitis complicated by cavernous transformation of the portal vein: contraindication to surgery? *Surgery* 2011;149(3):321–328.
- Adam U, Makowiec F, Riediger H et al. Pancreatic head resection for chronic pancreatitis in patients with extrahepatic generalized portal hypertension. *Surgery* 2004;135(4):411–418.
- Kempeneers MA, Issa Y, Ali UA et al. International consensus guidelines for surgery and the timing of intervention in chronic pancreatitis. *Pancreatology* 2019;20(2):149–157.
- Diener MK, Rahbari NN, Fischer L et al. Duodenum-preserving pancreatic head resection versus pancreatoduodenectomy for surgical treatment of chronic pancreatitis: a systematic review and meta-analysis. *Ann Surg* 2008;247(6):950–961.
- Gaag NA van der, Gulik TM van, Busch ORC et al. Functional and medical outcomes after tailored surgery for pain due to chronic pancreatitis. *Ann Surg* 2012;255(4):763–770.
- Isaji S. Has the Partington procedure for chronic pancreatitis become a thing of the past? A review of the evidence. *J Hepatobiliary Pancreat Sci* 2009;17(6):763–769.
- Cataldegirmen G, Bogoevski D, Mann O et al. Late morbidity after duodenum-preserving pancreatic head resection with bile duct reinsertion into the resection cavity. *Br J Surg* 2008;95(4):447–452.
- Izbicki JR, Bloechle C, Broering DC et al. Longitudinal V-shaped excision of the ventral pancreas for small duct disease in severe chronic pancreatitis. *Ann Surg* 1998;227(2):213–219.